



Case Report

Volume 14 Issue 5 - October 2021

DOI: 10.19080/ADOH.2021.14.555900

Adv Dent & Oral Health

Copyright © All rights are reserved by Vladimira Dimitrova

Clinical Case of Conservative Retreatment of Compromised Tooth



Ivanka Dimitrova and Vladimira Dimitrova*

¹Department of Conservative Dentistry, Faculty of dental medicine, Medical University, Sofia, Bulgaria

²Faculty of dental medicine, Medical University, Sofia, Bulgaria

Submission: September 27, 2021; **Published:** October 08, 2021

***Corresponding author:** Vladimira Dimitrova, Faculty of dental medicine, Medical University, Sofia, Bulgaria

Abstract

This clinical case demonstrates the successful retreatment of chronic apical periodontitis complicated by iatrogenic Strip furcal perforation during root canal treatment (RCT), made by a dental student. Apical periodontitis (AP) is an inflammatory process of the periradicular tissues caused by a microbial infection. The risks of retreatment, especially in obliterated root canals and student treatment, are significant. In addition, perforations can increase the chance of treatment failure. Factors that have impact include location and size of the perforation, potential microbial colonization of the endodontic system, the time between the occurrence of the perforation and its repair as well as the filling material. The clinical case could be further complicated by perforation in the risk zone, which makes the expected outcome of treatment rather unfavorable. For a long-term success it is important to disinfect and sterilize both the perforated area and the root canals. The result of this retreatment has been tracked for one calendar year in the present study. It concluded that the examined clinical case is an example of a favorable outcome of treatment of a complicated situation and also demonstrates the correct clinical approach in terms of student learning.

Keywords: Periapical Periodontitis; Retreatment; Strip perforation

Abbreviations: RCT: Root canal treatment; AP: Apical periodontitis

Introduction

Modern dental science aims to improve patients' oral health by preserving as much teeth as possible. Apical periodontitis (AP), a prevalent dental disease, resulting from a microbial infection of the root canal system, is one of the main reasons for tooth extraction. The treatment and nature of the healing process of chronic AP is complex and depends on many factors. The success of root canal retreatment is affected by the correct choice of clinical protocol, removal of bacteria from infected root canals, control of secondary infection, size of periapical lesion, the restorability of the tooth and its strategic position in the dentition, periodontal health, the patient's health history and motivation, the skill level of the dentist Yamaguchi [1]. The basic factor influencing success is the preoperative status of the tooth. Teeth with an apical radiolucency show a 20% lower success rate than teeth without lesion Sjögren [2]. A size of periapical radiolucency greater than 2 mm diameter may have a negative outcome of RCT Ng YL [3]. The average success rates of nonsurgical endodontic re-treatments are around 70–80% Rosen [4]. The different complications during RCT may raise additional dilemmas during the decision-making process. We present a clinical case of retreatment of chronic apical

periodontitis, complicated by iatrogenic strip furcal perforation during RCT, made by 5th year student in a clinical student hall under the guidance of a supervisor. The strategic importance of the tooth and the patient's strong desire to keep it were crucial factors for the proceeding of the retreatment. Further factors which highly affect the treatment prognosis are time, size and shape of the perforation as well as its location. Moreover, controlling the infection at the perforated location is also of importance Aidasani & Mulay [5].

Case Report

A 45-year-old female patient visited the Department of Conservative Dentistry, Faculty of Dental Medicine, Medical University – Sofia, Bulgaria, with complaints of pain and discomfort when eating and slight swelling in the area of lower left first molar 36. The patient reported previous endodontic treatment of that tooth with acute symptoms when she was 18 years old. After treatment, the final recovery took place with the placement of a ceramic crown. The patient did not provide data on systemic diseases and allergies. During the intraoral examination

a tooth with a ceramic crown was present, the mucosa above the periapex was red, and a bulging vestibular sinus track, lightly red without a formed tip, was also observed. While palpating the mucosa in the area above the apex the patient felt slight pain and discomfort. A vertical percussion and mobility examination did not indicate any signs of pain. The radiographic examination done outlined a diffuse extensive flame-like radiolucency in the apex area of the distal root, destruction of lamina coritcalis apically

and gradual transition between the area of bone destruction to healthy surrounding bone filling, loss of lamina dura apically at both roots (Figure 1). A root canal filling at MV and ML canals was present; short, without reaching the foramen apicale, very thin and delicate, inhomogeneous shade of the filling which was an indication of insufficiently shaped and widened canal; shadow between the filling and the root wall.

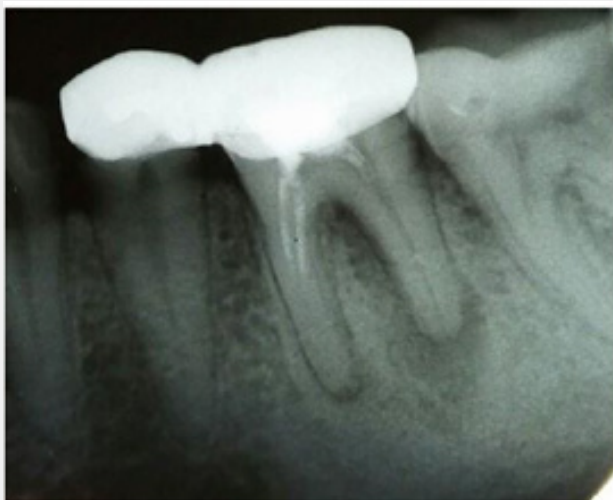

Figure 1: Perioperative status.

The patient was given informed consent stating that the treatment would be done by a student. The treatment started with a removal of the crown, followed by opening of the pulp chamber, locating all canals and removing the old root canal filling manually. During retreatment iatrogenic strip furcal perforation occurred due to an incorrect instruments stroke. The patient reported a feeling of strong pain and slight bleeding. The bleeding was stopped, and a radiography was performed in order to precisely

locate the perforation. (Figure 2). The perforation was located in the region of cervical mesio-vestibular canal (Figure 3)? After the bleeding was stopped, the perforated area was irrigated with 2% sodium hypochlorite and dried again, followed by sealing with gray MTA Angelus (Angelus, Londrina, PR, Brazil) and then an absorbent cotton roll was placed over the seal. X-ray sealing quality control was also performed (Figure 4).

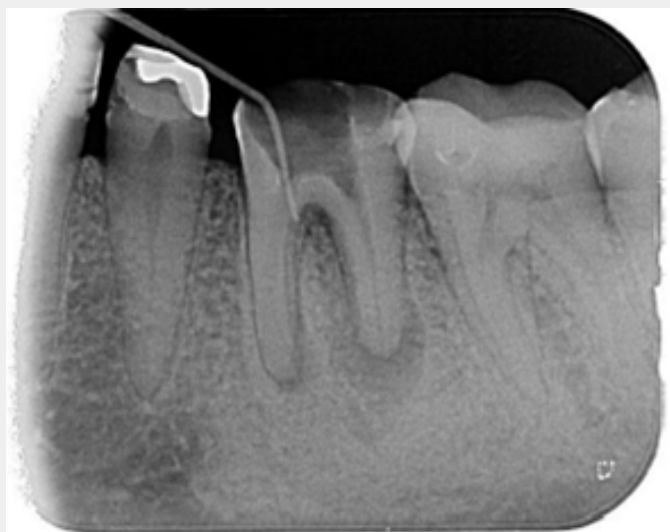

Figure 2: location of perforation.

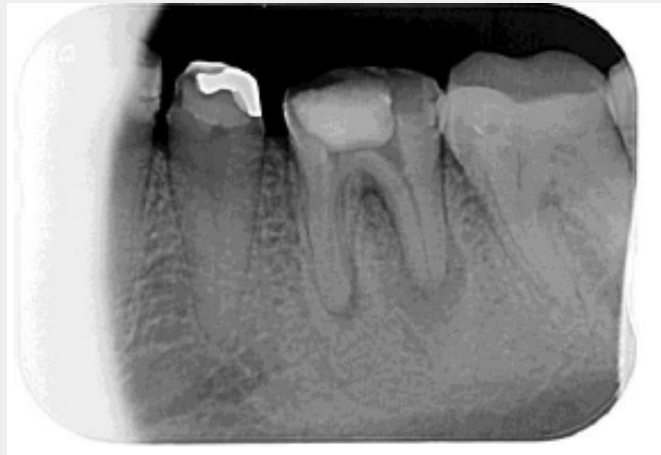

Figure 3: Strip furcal perforation.

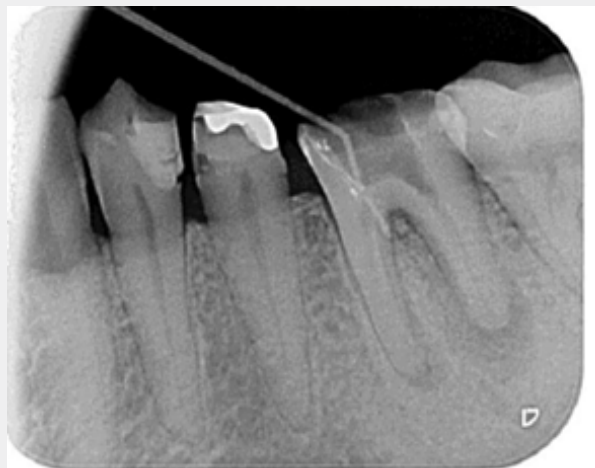


Figure 4: X-ray sealing quality control.

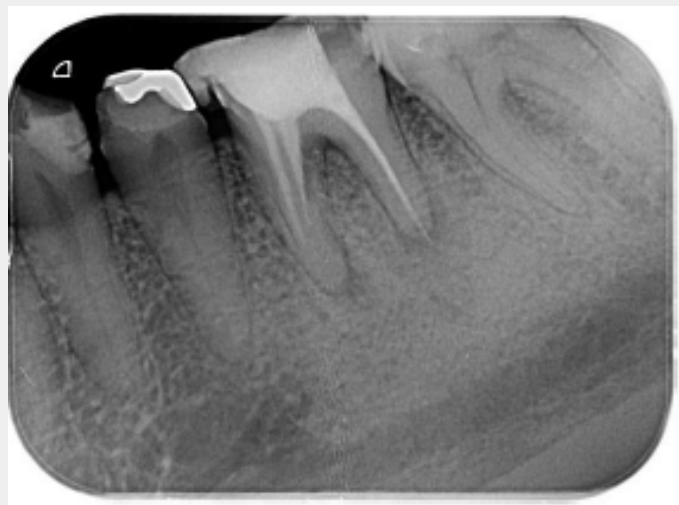


Figure 5: Radiographic evaluation after treatment and root canal filling.

During the follow-up appointment the shaping of the canals was initiated with constant irrigation with sodium hypochlorite 2 % and saline irrigation to eliminate MO and fixate necrotic matter in RC. This was done to remove the contaminant layer and prevent and/or reduce pain as well as provide suitable conditions for the healing process. The working length was determined by an apex locator - Apex locator Woodpex V and an X-ray. Manual canal instruments were used for the shaping of the root canals. The master apical file for MV canal is №35- 15mm, ML-№40-13 mm, DV- №35-16mm, DL-№35- 16mm. Furthermore, a pale-yellow serous exudation was discovered. It was not abundant but could have compromised the treatment. This required a standard alternating

irrigation, intracanal medicament $\text{Ca}(\text{OH})_2$. Thus, paste was applied with iodoform for a period of 1 week and temporary filling was placed. Considering the clinical discovery, three iontophoresis procedures were prescribed along with Metronidazole. The filling of the root canals was with MTA Angelus. A control radiography showed accurate and homogeneous root filling (Figure 5). The choice of using calcium silicate cement was based on the results of previous studies Dimitrova. 12 months following treatment, the patient did not have clinical pain or discomfort during eating and radiographically. The bone defect was repaired almost completely (Figure 6).

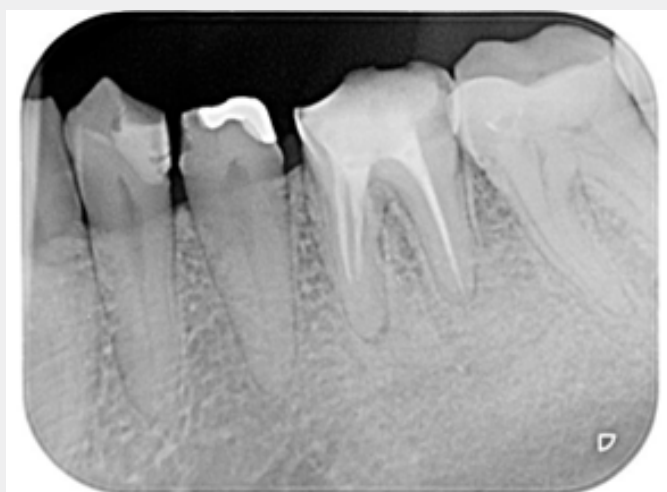


Figure 6: Radiographic changes during healing of chronic apical periodontitis after root canal filling.

Discussion

Multiple challenges are posed for the clinical practice due to the dynamic characteristics of apical periodontitis. The purpose of an endodontic treatment is to prevent and/or eliminate the pathological process of endodontic origin. Treatment of chronic AP is typically associated with successful long-term results, and if there are any indications of failure, a further surgical treatment is considered. Accidents with worse prognosis include perforations at the furcation due to its proximity to the gingival sulcus which favors bacterial contamination Seltzer. Iatrogenic strip furcation perforation is critical for a good outcome. Aidasani & Mulay [5]. Influential factors of significance to the prognosis for treatment are time, size, and shape of the perforation as well as its location which impacts the potential to control the infection. Frequently, the cause is iatrogenic as a result of the misaligned use of rotary burs amid endodontic access preparation and search for root canal orifices. Aidasani & Mulay [5]. Our aim is to avoid an inflammatory process in the periodontal area with exacerbation and also the development of irreversible bone loss. It should be noted that treatment of a tooth with chronic AP with perforation is a challenge even for experienced endodontists Gorni. Treating such a difficult and complicated case by a fifth-year student is

also very challenging. Introduction of bioactive calcium silicate cements in dental practice is an important prerequisite for success in the treatment of compromised cases. Similar conclusions have been confirmed by other authors Camilleri J & Montesin; Mente J & Hage.

Conclusion

This clinical case is an example of a favorable outcome of treatment of a complicated situation and also demonstrates the correct clinical approach in terms of student learning.

References

1. Yamaguchi MY, Noiri Y, Itoh (2018) Factors that cause endodontic failures in general practices in Japan. *BMC Oral Health* 18(70): 1-5.
2. Sjögren UB, Hägglund G, Sundqvist K, Wing (1990) Factors affecting the long-term results of endodontic treatment. *J Endod* 16(10): 498-504.
3. Ng YL, Mann V, Gulabivala K (2011) A prospective study of the factors affecting outcomes of nonsurgical root canal treatment: part 1: Periapical health. *Int Endod J* 44(7): 583-609.
4. Rosen E, Azizi H, Friedlander C, Taschieri S, Tsesis I (2014) Radiographic identification of separated instruments retained in the apical third of root canal-filled teeth. *J Endod* 40(10) 1549-1552.
5. Aidasani GL, Mulay S (2018) Management of iatrogenic errors: Furcal perforation. *J Int Clin Dent Res Organ* 10(1): 42-46.



This work is licensed under Creative Commons Attribution 4.0 License
DOI: [10.19080/ADOH.2021.14.555900](https://doi.org/10.19080/ADOH.2021.14.555900)

**Your next submission with Juniper Publishers
will reach you the below assets**

- Quality Editorial service
- Swift Peer Review
- Reprints availability
- E-prints Service
- Manuscript Podcast for convenient understanding
- Global attainment for your research
- Manuscript accessibility in different formats
(Pdf, E-pub, Full Text, Audio)
- Unceasing customer service

Track the below URL for one-step submission
<https://juniperpublishers.com/online-submission.php>